

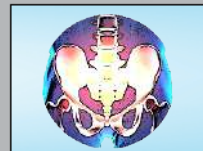
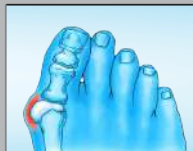
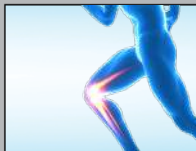
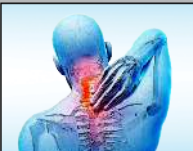
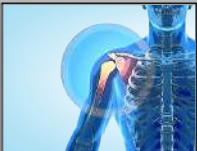
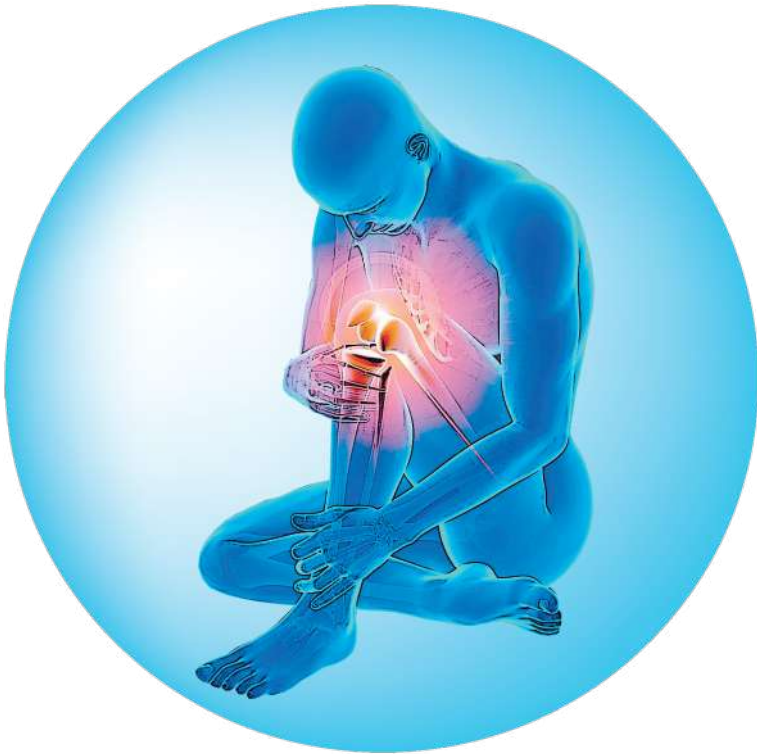
**asia medical specialists**  
亞洲專科醫生



ISO 9001:2015  
FS 550968

## Patellofemoral Pain



Anterior Knee Pain – or pain at the kneecap - is a very common complaint. Most anterior knee pain is from the joint between the kneecap (patella) and the thigh bone (femur), known as the patellofemoral joint.

### Patellofemoral biomechanics

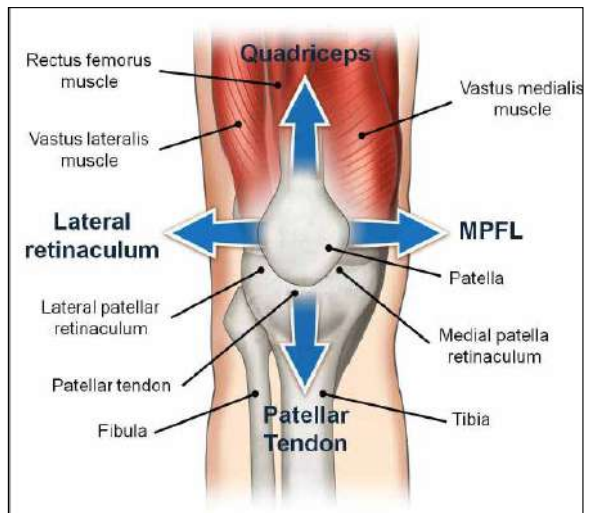
The patella is a sesamoid bone in the knee extensor tendon. Its function is to reduce friction and improve leverage as the knee bends through its giant arc of motion. It is subjected massive loads, up to several times body weight, as the knee bends, and therefore has the thickest articular cartilage in the body. The patella articulates with the trochlea groove in the femur to form the patellofemoral joint. When the knee is straight the patella 'floats' without much constraint, and as the knee bends the patella enters the trochlea groove.

The patella connects the quadriceps tendon in the thigh to the patellar tendon below the knee attaching to the tibial tuberosity of the shin bone.

On the inside and outsides of the patella are the medial and lateral retinaculæ – sheets of tough fibrous tissue which stop the patella from moving too far from side to side.

Ideally the forces acting on the patella are balanced, to provide stability and maintain proper tracking (fig. 1).

Even minor alterations in the knee joint mechanics can profoundly affect patellofemoral loads. Flatow 1 showed a dramatic reduction of contact area with simulated 5 degrees tilting and 5mm sideways shifting of the patella, causing very high peak loads on the cartilage, which could result in pain, cartilage damage, and arthritis.



**Fig. 1** Forces acting on the patella

## Assessment

Accurate diagnosis is the basis of successful treatment.

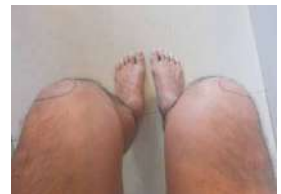**History.** Patients describe pain primarily in the front of their knees, worse with stairs - especially going down. They frequently experience pain with prolonged sitting (e.g. watching a movie, sitting in an aeroplane) and feel that they have to occasionally straighten their legs to decrease discomfort. The pain is usually exacerbated by squatting and kneeling. It is generally an aching pain, but can be sharp or burning. This occurs particularly when going down the stairs. The problem often begins after taking up a new activity or increasing the intensity of an activity.

One of the most important features is *giving way*. The patient may report that something jumps in the knee or something is out of place momentarily, causing a sense of instability. Sometimes people fall down.

**Examination.** The goals are to locate the painful structure and to assess factors that affect patellar forces and alignment.

### Look

- Valgus (knock) knees;
- 'Squinting' patellae (fig. 2);
- Flat feet;
- Increased foot progression angle (Charlie Chaplin);
- Decreased foot progression angle ('pigeon toed');
- Positive "J sign" (the patella following an upside down J shaped track - moving sideways on knee extension as it leaves the trochlea groove and is pulled laterally by tight lateral structures).



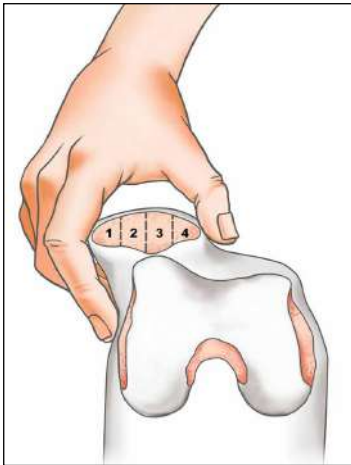
**Fig. 2** Squinting patellae

### Feel

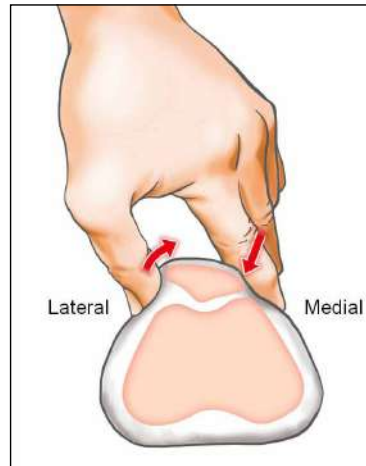
- Patellar tenderness
- Infrapatellar fat pad tenderness
- Patellar tendon tenderness
- Quadriceps tendon tenderness
- Tender pre-patellar, infra-patellar or anserine bursae

### Move

- Generalised ligament laxity, according to Beighton's criteria <sup>2</sup> (table 1), which is associated with patellar instability.
- Active and passive knee motion.
- Patellar crepitus.
- Patellar glide test (fig. 3).
- Patellar tilt test (fig. 4).
- Knee ligament stability – especially PCL laxity, which increases patellofemoral pressures.
- Hip rotation – internal and external rotation should be equal – if not there may be a torsional deformity.
- Thigh foot angle is measured to identify torsional deformity.



**Fig. 3** Patellar gliding test. The kneecap can be manually displaced both medially and laterally between 25% and 50% of width of the patella. Minimal displacement signifies retinacular tightness.



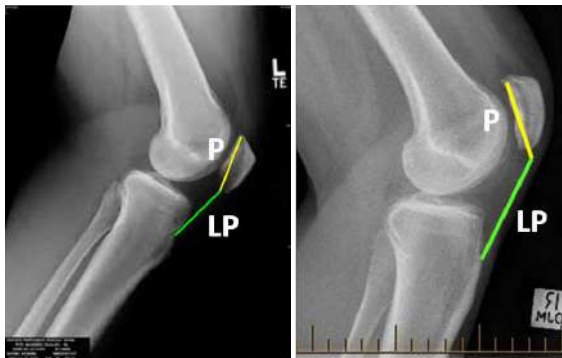
**Fig. 4** Patellar tilt test. With the knee in 20 degrees of flexion, the examiner attempts to flip the lateral edge of the patella upwards. Normally the patella should be tilted upwards above the horizontal.

Table 1		Left	Right
1.	Passive hyperextension of the little finger MCP joint beyond 90° with the forearm and hand flat on a table	1	1
2.	Passive apposition of the thumb to the flexor aspect of the forearm	1	1
3.	Passive hyperextension of the elbow beyond 10°	1	1
4.	Passive hyperextension of the knee beyond 10°	1	1
5.	Active forward flexion of the trunk with the knees fully extended so that the palms of the hands rest flat on the floor	1	-
TOTAL		/ 9	

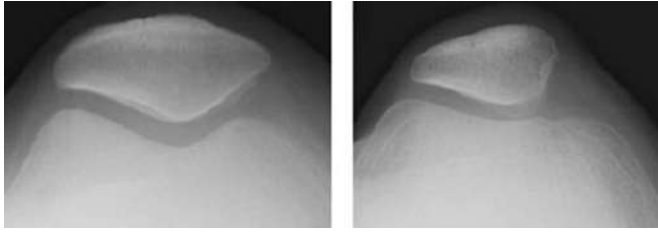Table 1 Beighton’s criteria for generalised ligament laxity. Scores over 4 out of 9 signify joint hypermobility

Radiology

- X-rays. Three views for patellofemoral problems:
  1. anteroposterior,
  2. true lateral (fig. 5)
  3. Laurin’s skyline view (fig. 6) with the knee in 30 degrees flexion.



**Fig. 5** Left: Normal patella with normal Insall-Salvati ratio.  
Right: ‘Patella alta’ with increased Insall-Salvati ratio.



**Fig. 6** Laurin's views: left: normal; right: dysplastic trochlea and patella.

- *Computerised tomography (CT)* is used to assess the rotational alignment of the lower limb – looking for torsional deformities of femur and tibia. This requires scanning the hip, knee and ankle at the same time.
- *Magnetic resonance imaging (MRI)* will reliably demonstrate the knee ligament conditions and cartilage problems around the patella.

## Treatment

If specific underlying damage, such as posterior cruciate ligament ruptures or meniscal tears are identified, these are treated. Bursitis (housemaid's or clergyman's knee) also has specific treatment. If no specific damage is identified, treatment is directed to the patellofemoral joint.

### Biomechanical patellofemoral pain syndrome

This is pain at the front of an apparently undamaged knee, thought to be from abnormal mechanical stresses to the patellofemoral joint. The precise cause of the pain is not clear<sup>3</sup>, however the symptoms are thought to be from the abnormalities outlined above, which cause excessive loads on the patellofemoral joint surfaces.

#### Treatment:

- Activity modification (avoiding activities that bring on symptoms such as climbing stairs, squatting or lunging).
- Physiotherapy supervised stretching and strengthening programme – particularly:
  - o Gluteus maximus stretches
  - o Quadriceps strengthening<sup>4</sup>

- Anti-inflammatory medication – for temporary pain relief – especially to allow physical therapy exercises.
- Orthotics to correct flat feet, though data is slightly inconclusive.

### Operation:

**Arthroscopy.** Lateral retinacular release is suggested if non-operative treatments. It is particularly helpful in patients with tilted patellae because of lateral retinacular tightness. It may be combined with medial retinacular tightening, both of which can be performed by a minimally invasive arthroscopic procedure <sup>5-7</sup>.

**Rotational osteotomy.** If the CT scan reveals that the thigh bone and/or the shin bone are twisted, causing the knee to face the wrong direction, this can be corrected by operation to twist the bones into the correct position. The procedure involves cutting the bones ('osteotomy') and fixing them in the correct position while they heal. This can be very helpful <sup>8,9</sup>, including in patients who have had other knee operations, but have continuing pain <sup>10</sup>.

### Isolated patellofemoral osteoarthritis

Isolated patellofemoral osteoarthritis occurs in about 10% of patients with knee arthritis. It may be caused by injury or may follow chronic biomechanical patellofemoral pain. Patellofemoral arthritis (fig. 7) occurs when the articular cartilage in the trochlear groove of the femur and on the underside of the patella wears out. When the wear is severe, the underlying bone may become exposed. Moving the bones along this rough surface is painful.

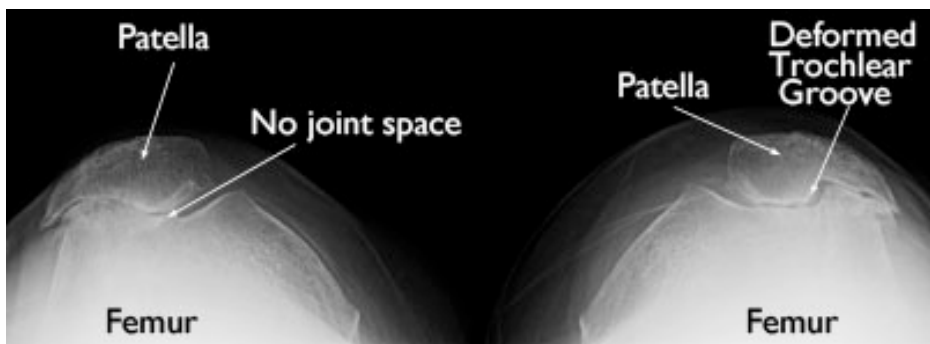


Fig 7 Osteoarthritis of patellofemoral joint

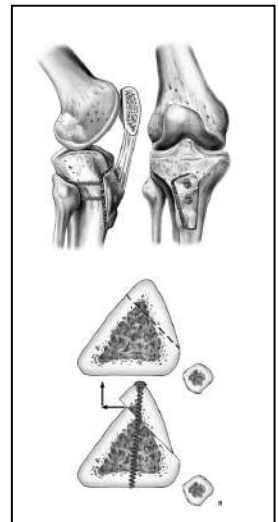
Initial treatment is a combination of treatment of biomechanical patellofemoral pain and of osteoarthritis in general:

- Glucosamine 1.5 grams once a day long-term <sup>11, 12</sup>.
- Activity modification (avoiding activities that bring on symptoms such as climbing stairs, squatting or lunging).
- Physical therapy supervised stretching and strengthening programme – particularly:
  - o Gluteus maximus stretches
  - o Quadriceps strengthening <sup>5</sup>
- Anti-inflammatory medication – for temporary pain relief – especially to allow physical therapy exercises
- Visco-supplementation (e.g. hyaluronic acid injections).

Surgery is an option if non-operative treatment fails.

The type of surgical procedures depends on the severity of the arthritis and associated causes:

- **Arthroscopy: lateral retinacular release +/- medial plication +/-chondroplasty.** A minimally invasive arthroscopic procedure can help. In chondroplasty the rough arthritic joint surfaces are smoothed, which reduces catching. Chondroplasty is an option in cases of mild to moderate cartilage wear.
- **Tibial tuberosity transfer** also called Fulkerson osteotomy (fig. 8). This procedure can help relieve pain in patients with arthritis in specific portions of the patella. Shifting the tibial tuberosity, which is the insertion of the patellar tendon onto the shinbone, changes the position of the kneecap, reducing pressure on the arthritic areas and relieving pain <sup>13</sup>.

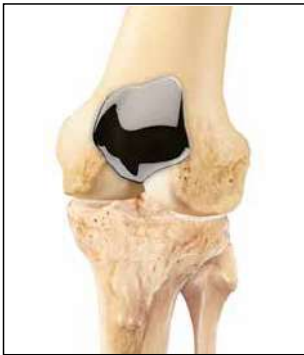

**Fig. 8** Fulkerson osteotomy.

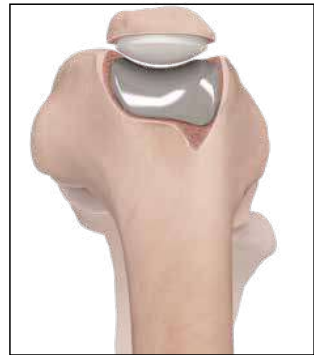

- **Patellofemoral replacement.** This is a partial knee replacement. The worn cartilage surfaces are removed and replaced with thin metal and plastic implants. The trochlear groove is covered by a thin metal cover (fig. 9) and a polyethylene button is used on the patella (fig. 10).

This is a relatively new form of knee replacement, but the medium-term results are generally good <sup>14, 15</sup>. If needed, it can be revised to a total knee replacement, so it does not burn any bridges.



**Fig. 9** (Left) Partial knee replacement – the metal cover on the trochlea groove of the femur is seen with the patella removed.



**Fig. 10** (Right) Partial knee replacement – the metal cover on the trochlea groove of the femur and the plastic button on the patella are seen with the knee bent, as in Laurin's skyline X-ray.

## References

For the references of this article, please refer to the full version on our website: [www.asiamedicalspecialists.hk](http://www.asiamedicalspecialists.hk).

# MUSCULOSKELETAL TEAM



**SPINE**  
Dr HT CHOW



**SHOULDER**  
Dr Kelvin TAM



**HAND, WRIST,  
ELBOW &  
MICROVASCULAR**  
Dr Sally CHENG



**KNEE**  
Dr CC KONG



**HIP & PELVIS**  
Dr Jason BROCKWELL



**KNEE**  
Dr Terence CHAN



**CHILDREN &  
SCOLIOSIS**  
Dr Bobby NG



**FOOT & ANKLE**  
Dr SW KONG



**PAIN MEDICINE**  
Dr Peggy LI

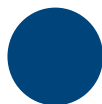

**OSTEOPOROSIS**  
Prof Clive COCKRAM



**RHEUMATOLOGY**  
Dr CK SUNG





**asia medical specialists**

亞洲專科醫生

商界展關懷

**caring company** 2019/20

Awarded by The Hong Kong Council of Social Service  
香港社會服務聯會頒發

# MEDICAL & SURGICAL TEAM



**ENDOCRINOLOGY**  
Prof Clive Cockram



**HYPERTENSION & LIPIDS**  
Prof Brian Tomlinson



**CARDIOLOGY**  
Dr Peter Wong



**RHEUMATOLOGY**  
Dr CK Sung



**BRAIN SURGERY**  
Dr YT Kan



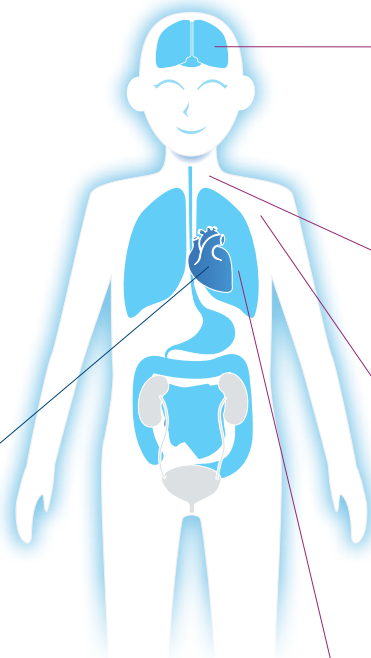
**BREAST, HEAD & NECK SURGERY**  
Dr James Kong



**BREAST, THYROID & GENERAL SURGERY**  
Dr Sammy Chuang



**ABDOMINAL & CHEST SURGERY**  
Dr YP Tai



**Hong Kong** 8/F China Building, 29 Queen's Road Central  
**Kowloon** 1210, 12/F Ocean Centre, 5 Canton Road, Tsimshatsui  
info@asiamedical.hk      www.asiamedicalspecialists.hk

**Tel** +852 2521 6830  
**Tel** +852 3420 6666  
**Fax** +852 2521 6831



## More articles are available on our website

### Knee

- ACL FAQs
- Articular Cartilage Injuries in the Knee FAQs
- Biological Knee Replacement (BKR) FAQs
- Meniscal Regeneration by Meniscal Scaffold Implant Actifit Polyurethane Scaffold
- Meniscus FAQs: Tears, Repairs & Transplants
- OA Knee FAQs
- Patellofemoral Pain

### Spine

- Adult Scoliosis FAQ
- 'Slipped Disc' FAQs
- Diagnosis of Low Back Pain FAQs
- Lumbar Disc Replacement FAQs
- Lumbar Spinal Stenosis FAQs
- Sacroiliac Joint Pain FAQs
- Treatment of Cervical Disc Hernia or Degeneration

### Shoulder

- Clavicle Fracture FAQs
- Is It Really Frozen Shoulder?

### Hand and Wrist

- Carpal Tunnel Syndrome FAQ's
- Common Hand Disorder

### Hip

- Acetabular Dysplasia FAQs
- Choosing among different types of hip replacement FAQs
- Femoro-Acetabular Impingement (FAI) FAQs
- Hamstring Tendon Tears FAQs

### Foot and Ankle

- Achilles Tendinopathy FAQs
- Ankle Sprain FAQs
- Bunions FAQs
- Chronic Pain after Ankle Injury
- Hallux Rigidus FAQs
- Minimally Invasive Surgery in the Foot & Ankle

### Children

- Juvenile & Adolescent Idiopathic Scoliosis FAQs
- Scoliosis: A Common Condition Which is Frequently Misunderstood

©2017 Asia Medical Specialists Limited. All rights reserved.